

Case Report

A CASE OF GASTROPARESIS SECONDARY TO A POSTERIOR FOSSA TUMOR

Esha Singhal^{1*}, Linah Omer¹, Raphael Mattamal¹

Author information: ¹Department of Pediatrics, Texas Tech University Health Sciences Center, Amarillo, Texas, USA, ²Northwest Texas Hospital, Amarillo, Texas, USA.

Received: 02-02-2022; Accepted: 12-19-2023; Published: 12-31-2023

Abstract: Introduction. Gastroparesis is an uncommon condition with scarce available literature. The presented child had a three-month history of persistent unexplained vomiting and inability to maintain adequate nutrition with severe gastroparesis on gastric emptying study. He was refractory to medical and surgical management.

Case Report. A 20-month-old male was brought into the ED and diagnosed with gastroenteritis. Abdominal X-ray was normal, and the vomiting persisted despite antiemetic (ondansetron) administration. He was started on bethanechol for gastroparesis, which was changed to intravenous metoclopramide as he did not tolerate the oral route. His presentation further progressed with intracranial hypertension, hydrocephalus, seizure, and acute respiratory failure necessitating intubation. He was subsequently diagnosed with an atypical teratoid rhabdoid tumor of the cerebellum, for which pediatric neurosurgery performed surgical resection.

Discussion. The patient was initially diagnosed with post-viral gastroparesis; however, he had shown poor response to medical and surgical therapy and later presented with developmental regression and signs of increased intracranial pressure leading to the diagnosis. In this case, we speculate that the development of gut dysmotility results from disruption of the dorsal motor nucleus of the vagus and autonomic nuclei in the brain stem, which may also have been the reason for medication resistance.

Conclusion. Pediatric gastroparesis is largely diagnosed as idiopathic; however, clinicians should be vigilant to look for secondary causes, especially in treatment-resistant cases.

Keywords: Gastroparesis, posterior fossa tumor, post-viral, gut motility, pediatrics.

INTRODUCTION In the pediatric population, gastroparesis is uncommon, with scarce available literature. In contrast to adults, it is noted that pediatric gastroparesis most commonly is idiopathic or post-viral [1]; rarely does it result from a primary neurologic disease process. Here, we present a case of a 20-month-old male with a three-month history of persistent unexplained vomiting and inability to maintain adequate nutrition found to have severe gastroparesis in a gastric emptying study. Initially, he was managed as post-viral gastroparesis, but he was refractory to medical and surgical management. Further, in the clinical course, the patient displayed developmental regression and abnormal mental status, which prompted

imaging of the brain. This led to the diagnosis of a posterior fossa tumor.

CASE REPORT A 20-month-old male with no significant past medical history presented with a four-week history of post-tussive, non-bloody, non-bilious emesis. He was previously experiencing symptoms of a viral URI with rhinorrhea, cough, fever, and vomiting after eating. After the first week of coughing and vomiting, he was brought into the ED and diagnosed with gastroenteritis. Abdominal X-ray was normal, and the vomiting persisted despite antiemetic (ondansetron) administration. He continued to have poor oral intake as well as decreased urine output for the subsequent three weeks. The patient was later admitted to the pediatric ward for dehydration management and further workup while being given ondansetron as needed. He had an 8-9% weight loss, and initial labs were notable for normal white cell count, thrombocytosis, normal anion gap metabolic acidosis, low

***Corresponding author:** Esha Singhal,
Texas Tech University Health Sciences Center, 1400 Coulter
str. Amarillo, TX, USA, 79106
Email: Esha.Singhal@ttuhsc.edu

bicarbonate (19 mg/dl), elevated Cl⁻ (108 mg/dl), normal urine specific gravity (1.017) and urine with trace ketones. Abdominal X-ray showed distended bowel loops and moderate stool but no obstruction; chest X-ray showed mild bilateral perihilar infiltrative markings, possibly viral in origin, but with no evidence of pneumonia. A gastric emptying study was also performed, and the patient ingested a scrambled meal labeled with 1mCi 99m technetium sulfur colloid (Figure 1).

Significantly delayed gastric emptying at 271 minutes and poor transit of the radiolabeled bolus were identified. The upper GI series was normal, and reflux was not identified.

He started on bethanechol for gastroparesis, which was changed to IV metoclopramide as he did not tolerate oral intake. He was maintained on intravascular fluids,

ondansetron for nausea, and pantoprazole. Due to nutritional deficits, the patient was started on continuous nightly nasoduodenal PediaSure Peptide (1kcal/mL). He was placed on tube feeds, encouraging oral intake during the day.

In the hospital he continued to have nausea and multiple episodes of vomiting during the day; initially, multiple trials to insert a transpyloric feeding tube by interventional radiology (IR) failed. Eventually, IR was able to place a weighted nasoduodenal feeding. He tolerated feeding increments up to 45 cc/hr via the feeding tube. After consulting with pediatric gastroenterologist, the patient was transferred into their care. A gastroenterologist proceeded to endoscopically dilate his pylorus due to

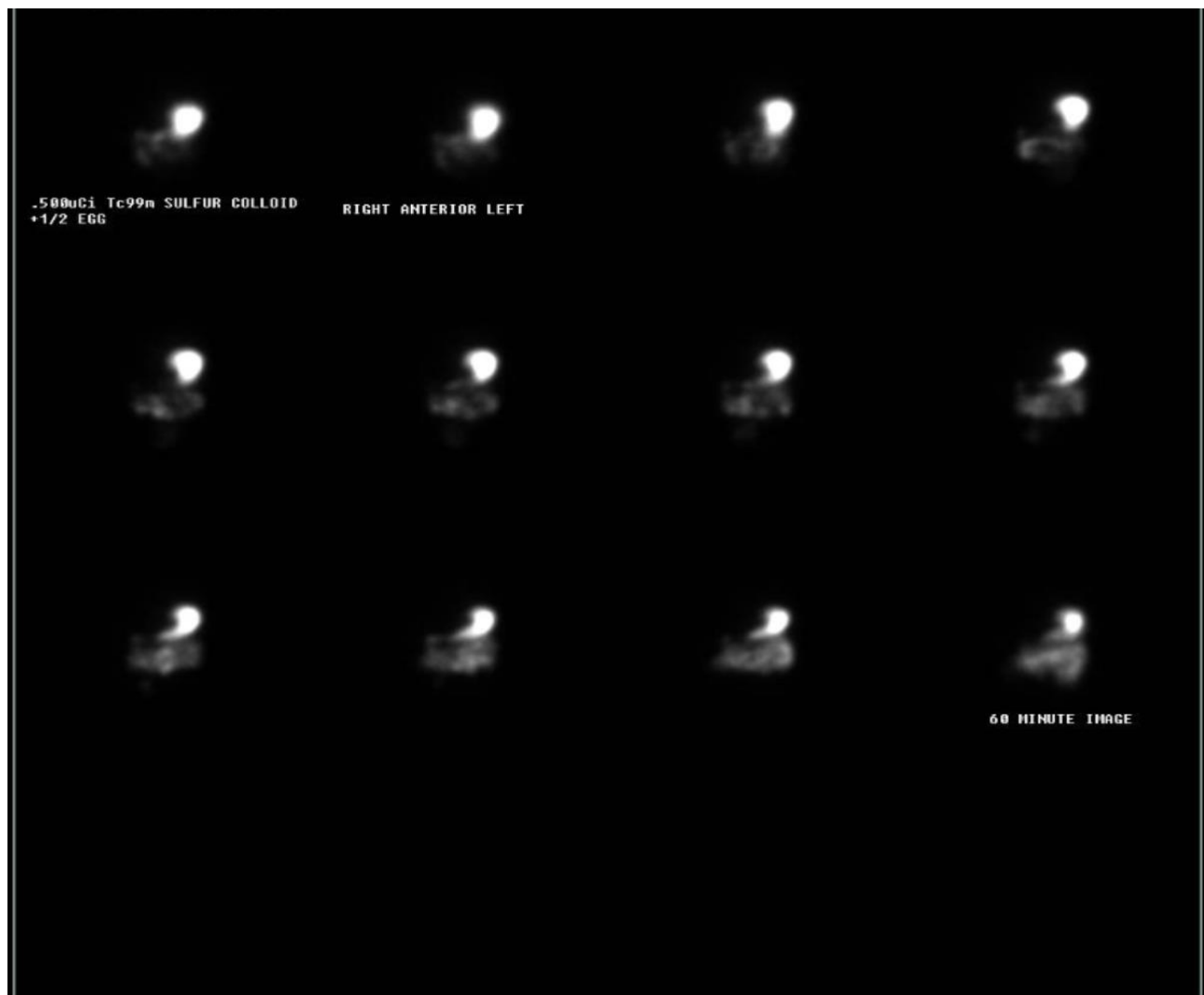

Figure 1. Gastric emptying studying indicates delayed gastric emptying of 271 minutes.

reported pyloric stenosis, and he was monitored at different facilities for continued emesis.

After discharge from the hospital his medical condition continues deteriorating and his GI dysfunction persisted despite the treatment. He was readmitted with worsened condition and with new findings of intracranial hypertension, hydrocephalus, seizure, and acute respiratory failure necessitating intubation. He was ultimately diagnosed with a posterior fossa tumor, found

to be an atypical teratoid rhabdoid tumor of the cerebellum (Figure 2).

He underwent a surgical resection of the tumor by pediatric neurosurgery with all resolution of the symptoms.

CONCLUSION We report a rare case of gastroparesis secondary to a posterior fossa tumor in a child to draw attention to this atypical presentation, especially since disruption of central control of gut motility can be an early

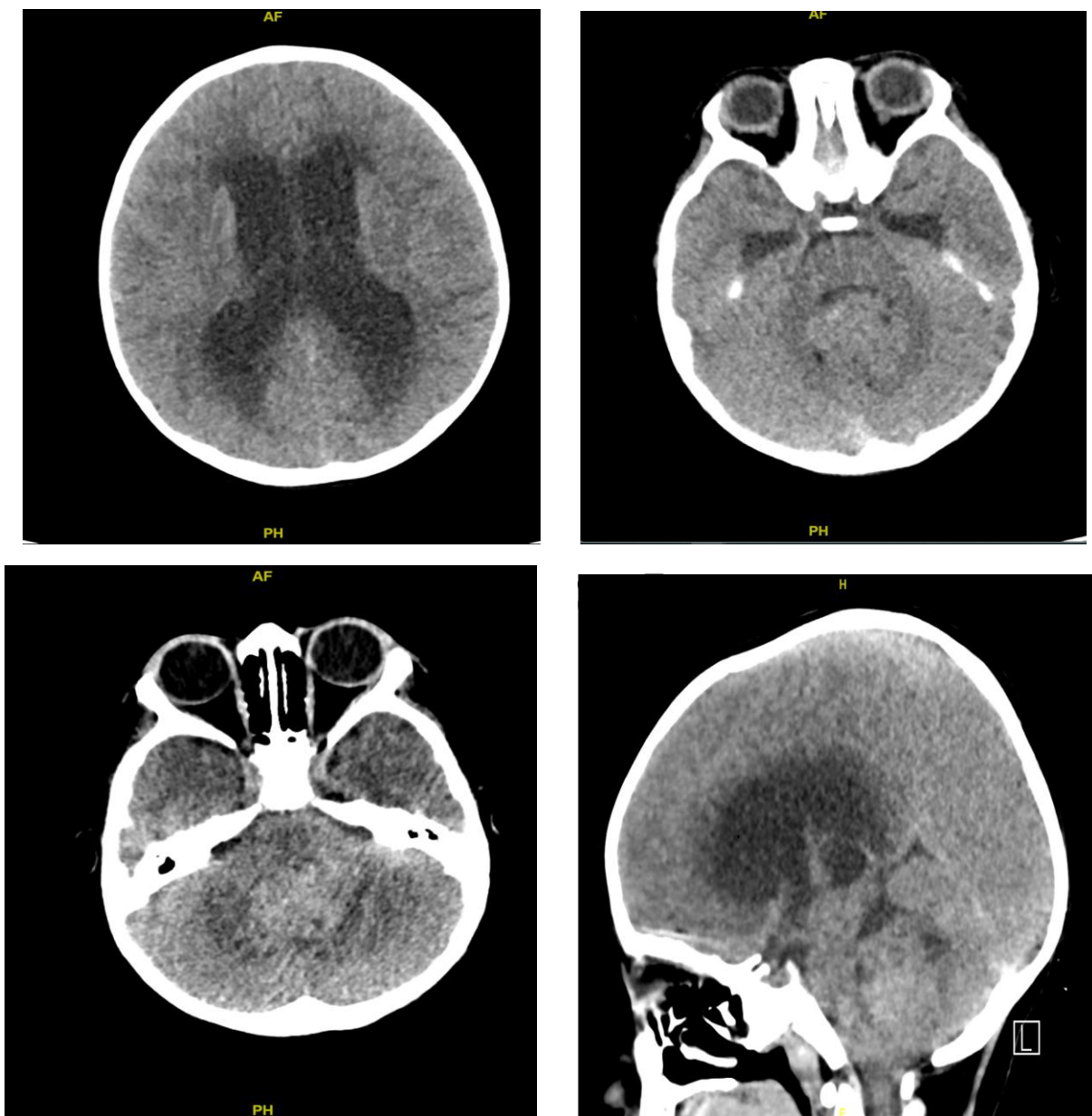


Figure 2. Non-contrast CT axial image of the head indicating a cerebellar mass.

manifestation of brainstem pathology. Pediatric gastroparesis is largely diagnosed as idiopathic; however, clinicians should be vigilant to look for secondary causes, especially in treatment-resistant cases. Further studies are needed to elucidate the pathophysiological processes underlying gastroparesis in children.

REFERENCES

1. Sigurdsson L, Flores A, Putnam PE, Hyman PE, Di Lorenzo C. Postviral gastroparesis: presentation, treatment, and outcome. *J Pediatr*. 1997;131:751-754.
2. Islam S. Gastroparesis in children. *Curr Opin Pediatr*. 2015 Jun;27(3):377-82. doi: 10.1097/MOP.0000000000000216. PMID: 25944312.
3. Rodriguez L, Irani K, Jiang H, Goldstein AM. Clinical presentation, response to therapy, and outcome of gastroparesis in children. *J Pediatr Gastroenterol Nutr*. 2012;55:185-190
4. Waseem S, Islam S, Kahn G, Moshiree B, Talley NJ. Spectrum of gastroparesis in children. *J Pediatr Gastroenterol Nutr*. 2012;55(2):166-72. doi: 10.1097/MPG.0b013e31824cf06e. PMID: 22314391.
5. Neural Control of the Gastrointestinal System- ClinicalKey. Accessed April 18, 2021. <https://www-clinicalkey-com.ezproxy.ttuhsu.edu/#!/content/book/3-s2.0-B9780128053539001145?scrollTo=%23h0000166>
6. Reddy SC, Bonino J, McCallum RW. Gastroparesis secondary to a demyelinating disease: a case series. *BMC Gastroenterol*. 2007 Jan 31;7:3. doi: 10.1186/1471-230X-7-3. PMID: 17266755; PMCID: PMC1800858.
7. Moshiree B, Potter M, Talley NJ. Epidemiology and Pathophysiology of Gastroparesis. *Gastrointest Endosc Clin N Am*. 2019;29(1):1-14. doi: 10.1016/j.giec.2018.08.010. PMID: 30396519.
8. Kovacic K, Elfar W, Rosen JM, Yacob D, Raynor J, Mostamand S, Punati J, Fortunato JE, Saps M. Update on pediatric gastroparesis: A review of the published literature and recommendations for future research. *Neurogastroenterol Motil*. 2020 Mar;32(3):e13780. doi: 10.1111/nmo.13780. Epub 2019 Dec 18. PMID: 31854057.
9. Szilagyi A, Stern J, Armanious S, Brem S. Gastroparesis secondary to a medulloblastoma of the posterior fossa. *Clin Nucl Med*. 1987;12(11):864-6. doi: 10.1097/00003072-198711000-00009. PMID: 3427859.
10. Raghav S, Kipp D, Watson J, Spring W. Gastroparesis with multiple sclerosis. *Mult Scler*. 2006;12(2):243-4. doi: 10.1191/1352458506ms1294cr. PMID: 16629430.
11. Zhang H, Qing B, Zheng J. Gastroparesis Following Resection of a Fourth-Ventricle Ependymoma in a Child. *World Neurosurg*. 2018 Sep;117:190-194. doi: 10.1016/j.wneu.2018.06.078. Epub 2018 Jun 20. PMID: 29933085.
12. Naftali T, Yishai R, Zangen T, Levine A. Post-infectious gastroparesis: clinical and electrogastrographic aspects. *J Gastroenterol Hepatol*. 2007;22:1423-1428.
13. Mohammadi S, Kolimarala V, Banoub H. Gastric emptying study in paediatric gastroparesis: what is the normal range? *J Paediatr Gastroenterol Nutr*. 2017;64:375.
14. ASGE Standards of Practice Committee, Fukami N, Anderson MA, et al. The role of endoscopy in gastroduodenal obstruction and gastroparesis. *Gastrointest Endosc*. 2011;74:13-21.