

Case Report

XANTHOGRANULOMATOUS PYELONEPHRITIS

Daniella Bello¹, Dianne Srinilta¹, Alya Abuhantesh¹, and Janet Meller^{1*}

Author information: Department of Pediatrics Texas Tech University Health Sciences Center at Amarillo, 1400 S Coulter St, Amarillo, TX, USA, 79106, e-mail: janet.meller@ttuhsc.edu

Abstract: Xanthogranulomatous pyelonephritis (XPN) is an uncommon form of chronic pyelonephritis and extremely rare in pediatrics. A six-year-old female presented with a six-month history of recurrent urinary tract infections treated with multiple antibiotics without clinical improvement. Computerized tomography (CT) of the patient's abdomen/pelvis showed a right renal mass that extended posteriorly into the perinephric space and the right psoas muscle. A CT-guided percutaneous biopsy was performed that ruled out malignancy and showed XPN. Although very rare, XPN should be considered in patients with recurrent or persistent infections of the kidney.

Key words: Xanthogranulomatous, pyelonephritis, child, pediatric surgery, kidney

INTRODUCTION Xanthogranulomatous pyelonephritis (XPN) is an uncommon form of chronic pyelonephritis often mistaken for a renal malignancy [1-3]. The etiology appears to be related to a combination of renal obstruction and chronic infection [4,5]. XPN is more common in adults than children and is not well studied in children due to the limited number of reported cases. Most pediatric cases occur in children <10 years of age. Urinary tract infections were reported in 70-85% of cases [1]. Other etiologies include congenital abnormalities such as uretero-pelvic junction obstruction and vesicoureteral reflux. Alterations in immune response and lipid metabolism, as well as lymphatic obstruction, malnutrition, arterial insufficiency, venous occlusion and hemorrhage, and necrosis of the pericalyceal fat have been contributing factors.

We present a female patient with chronic urinary tract infection and XPN treated with a total right nephrectomy.

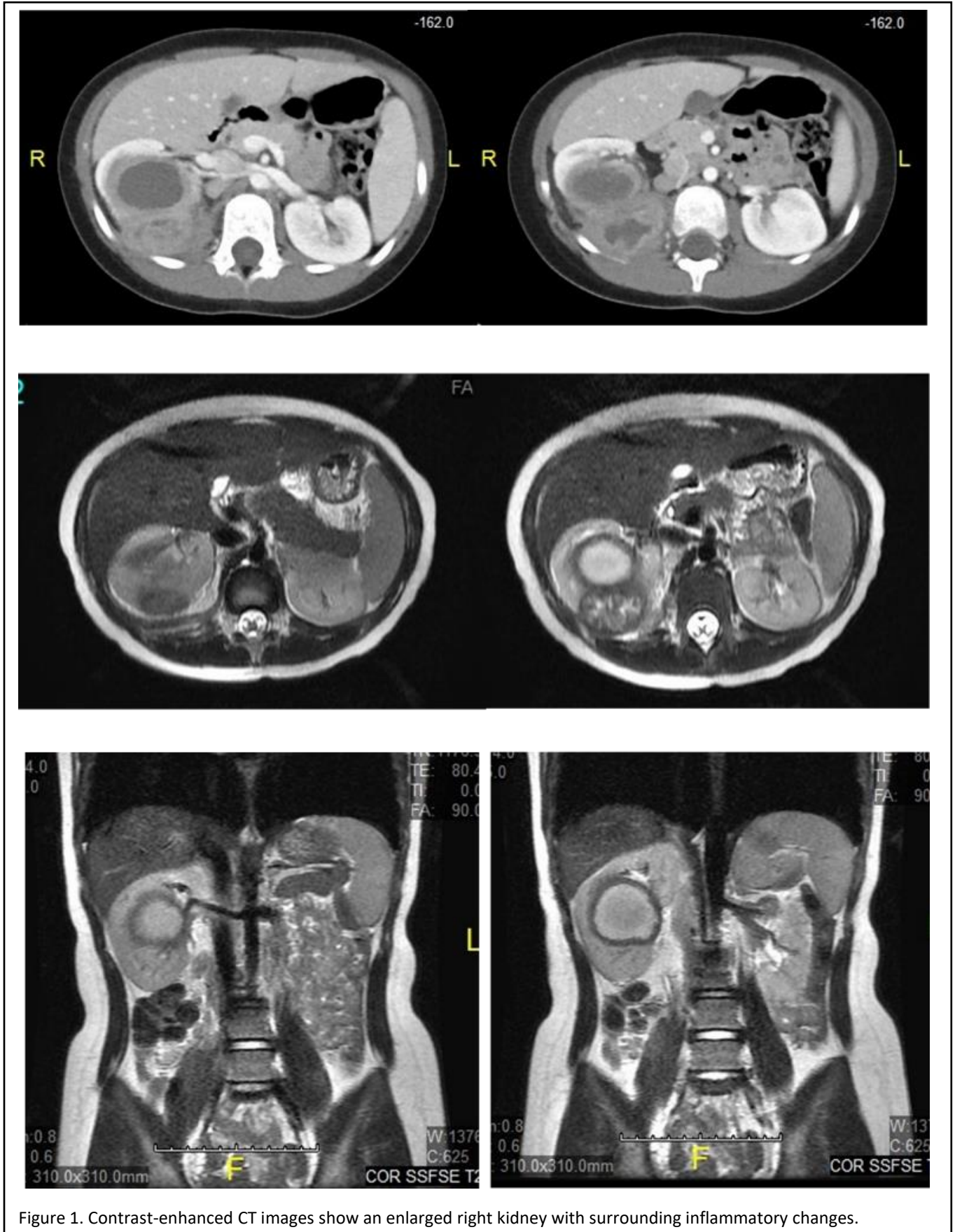
CASE PRESENTATION A six-year-old female presented as an outpatient with a six-month history of recurrent urinary tract infections treated with multiple antibiotics without

clinical improvement. A renal ultrasound showed a cystic mass in the right renal pelvis, a dilated pelvis, and a possible uretero-pelvic junction obstruction. A MAG 3 renal scan showed hydronephrosis of the right kidney with no evidence of obstruction. The patient lost her insurance coverage and was not able to follow up with an ordered CT scan at 6 months. When the family reestablished insurance, a CT of the abdomen/pelvis demonstrated a right renal mass extending posteriorly into the perinephric space and the right psoas muscle [Figure 1].

The mass was thought to represent a primary renal tumor or a possible rhabdomyosarcoma with associated right retroperitoneal lymphadenopathies. A workup for renal malignancy included a renal biopsy and oncology consultation. Due to the high suspicion of malignancy, a port was placed at that time. The biopsy results ultimately ruled out malignancy and showed XPN. The patient was admitted for a right nephrectomy and removal of the port [Figure 2].

DISCUSSION XPN is a granulomatous disease characterized by suppurative inflammation that leads to renal parenchymal destruction [6]. Lipid-laden macrophages replace the renal parenchyma and cause renal parenchymal destruction. It is uncommon in the pediatric population. The patient we described presented at a very young age, which is very unusual. Her form of XPN is the rarest form in the pediatric population. It affects females more often than males and can mimic a tumor. XPN is characterized by

*Corresponding author: Janet Meller
1400 S. Coulter str., Amarillo, TX, USA, 79106,
e-mail: janet.meller@ttuhsc.edu



abdominal or flank pain, fever, and a palpable abdominal mass on physical exam [1,2,4]. Overall, clinical symptoms of XPN are non-specific and vary with fever, dysuria, pyuria, leukocytosis, and flank pain most frequently cited [6]. In this case, the patient had no abdominal or flank pain and minimal tenderness on exam.

A diagnosis of malignancy was high on the differential list due to the absence of symptoms for the 5-6 months before our patient presented. The diagnosis of XPN was confirmed by radiologic imaging and more importantly by pathology. XPN showed a typical finding on contrast-enhanced CT, including dilated renal calyces, renal calculus, inflammatory changes to an enlarged kidney, and abscess formation [7].

Treatment typically consists of antibiotics and total or partial surgical resection of the affected kidney. Nephrectomy is the treatment of choice. XPN shows a high mortality rate if left untreated [6].

CONCLUSION XPN is an uncommon disease in children and the clinical and radiographic findings make the diagnosis hard to differentiate from renal malignancies. XPN should be considered in patients with recurrent or persistent infections of the kidney.

REFERENCES

1. Bonsib SM. Nonneoplastic diseases of the kidney. In *Urologic Surgical Pathology* (3rd ed.). Philadelphia, PA: Elsevier/Saunders, 2014.
2. Chlif M, Chakroun M, Rhouma SB, *et al*. Xanthogranulomatous pyelonephritis presenting as a pseudotumour. *Can Urol Assoc J*. 2016. 10; E36. doi.org/10.5489/cuaj.3225.
3. Dell'Aprovitola N, Guarino S, Vecchio WD, *et al*. 2014. Xanthogranulomatous pyelonephritis mimicking a renal cell carcinoma: a unique and challenging case. *Acta Radiol*. 3: 1-4. doi.org/10.1177/2047981613513763.
4. Lorca Álvaro J, Santiago González M, Laso García I. Xanthogranulomatous pyelonephritis. *Rev Clin Esp*. 2019, 15. pii: S0014-2565(19)30265-6. DOI:10.1016/j.rce.2019.06.012.
5. Borzymowski C, Clauw E, Bosquart J, Peru AS, Jourdain M. Xanthogranulomatous pyelonephritis. *Rev Prat*. 2019; 69: 399.
6. Lee JH, Kim SS, Kim DS. Xanthogranulomatous Pyelonephritis: "Bear's Paw Sign". *J Belg Soc Radiol*. 2019. 103: 31. doi: 10.5334/jbsr.1807.
7. Craig WD, Wagner BJ, Travis MD. Pyelonephritis: Radiologic-pathologic review. *Radiographics*. 2008; 28: 255–76. DOI: 10.1148/rg.281075171.

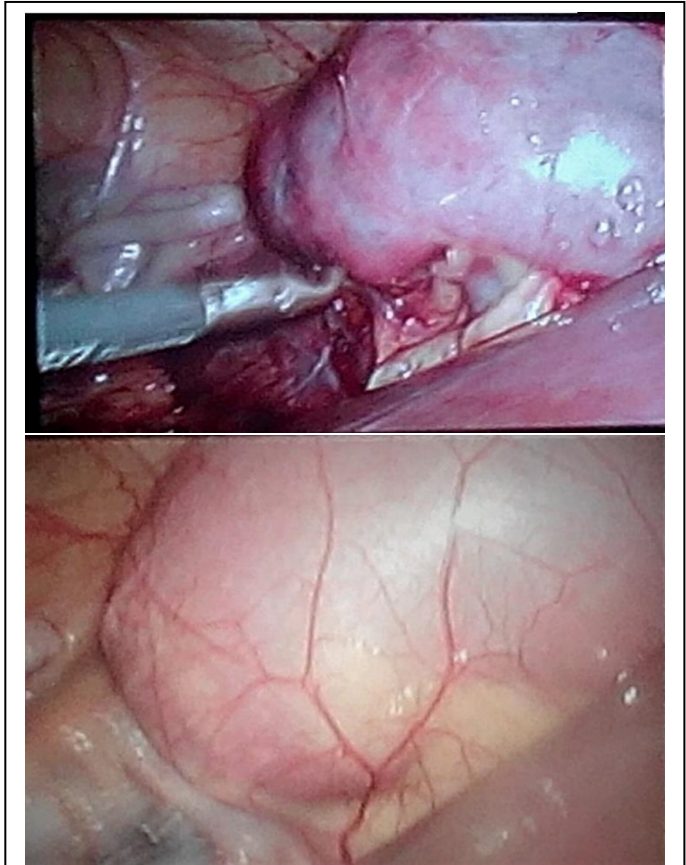


Figure 2. Surgical removal of XPN